

CASE STUDY.



Dr Peter
GIBSON



XPert WRIST 2.4:

Treatment of a severe
comminuted dorsal
angulated fracture with
fragment specific plating



Physician profile.

Dr. Peter GIBSON

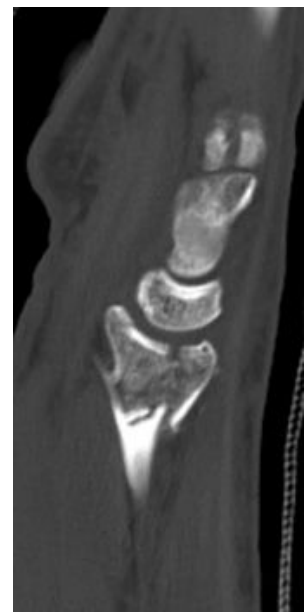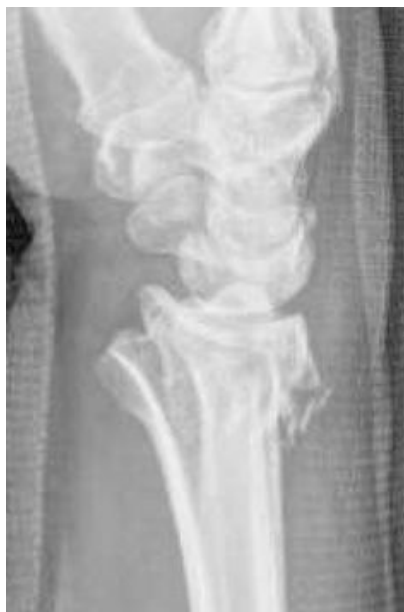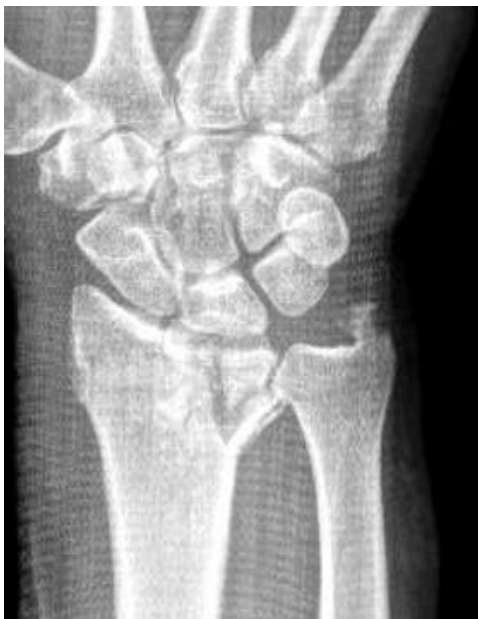Orthopedic Hand Surgeon, Flagstaff, Arizona, USA

Fellowship : Hand Center of San Antonio

Active member of : ASSH, AAOS

Patient history.

The patient is a young man of 18 years old with normal weight, who is an highly active rancher performing manor labor on a daily basis. He suffered a 23-C3 comminuted dorsally angulated distal radius fracture after a fall from a horse. Due to patient's high demand with need to return to heavy lifting, operative fixation of this fracture was determined to be the optimal treatment course, to help the patient to regain motion more quickly and ultimately to return to work without restrictions.



Pre-op x-rays

Surgical treatment.

After patient interview, and neurovascular exam, a temporary splint was placed allowing patient to be stabilized prior to outpatient surgery.

The Pre-op AP and Lateral radiograph demonstrated dorsal angulated fracture and a CT-Scan was obtained to further define fracture pattern. CT-scan revealed small volar lunate facet piece with less than 10 mm of cortical bone, a dorsal ulnar piece, and a radial styloid component. Fractures with this small lunate facet piece (<14 mm) have a tendency to escape volar when plated in a traditional fashion, causing long term complications.

This high-energy fracture morphology does not allow for volar locking plate, volar rim plate, or dorsal plating alone. Historically external fixation or dorsal bridge plating has been performed. In this case, fragment specific fixation techniques were chosen to allow for anatomic reduction and stabilization of the joint surface, and early post-operative motion ; advantages that cannot be obtained when bridging the joint.

Preoperative discussion was had with patient about risks and benefit of surgery as well as different options for operative fixation.

What about the surgical procedure ?

Operative approach was initiated through a dorsal approach to the wrist. Initially, a 5-7 cm incision was made just ulnar to Lister's Tubercle. Careful dissection was taken down to the level of the retinaculum, and the third dorsal compartment. The EPL was released and retracted radially, while the common extensor tendons were elevated off the floor of the 4th dorsal compartment allowing exposure to dorsal aspect of the distal radius. A small dorsal capsulotomy was performed to visualize joint surface of the distal radius.

Fragment specific fixation was initiated with the dorso-medial piece. Anatomically contoured plate was placed as distally and close to the ulna as possible, provisionally fixed with K-wires. A non-locking screw placed just proximal of the fracture allows for the plate to be used in buttress fashion, providing dorsal stabilization. Distal fixation was then secured with locking screw. Proximal screws were then placed to secure and stabilize the ulnar dorsal column.

Next, a traditionally volar approach was used to the wrist. Once adequate exposure was obtained, attention was focused on the volar-ulnar piece, allowing for anatomic reconstruction of the lunate facet. This volar piece was deemed to be unstable in the sagittal plane. A small volar hook plate was chosen for fixation. Care was taken to avoid soft tissue stripping of this volar-ulnar piece. Placing the 2 pronged hook just distal to the articular surface, two separate non-locking screws were used just proximal to the fracture to create a stable volar cortex and buttress construct. Fracture reduction was checked with intra-operative x-rays as well as via the dorsal capsulectomy and direct visualization.

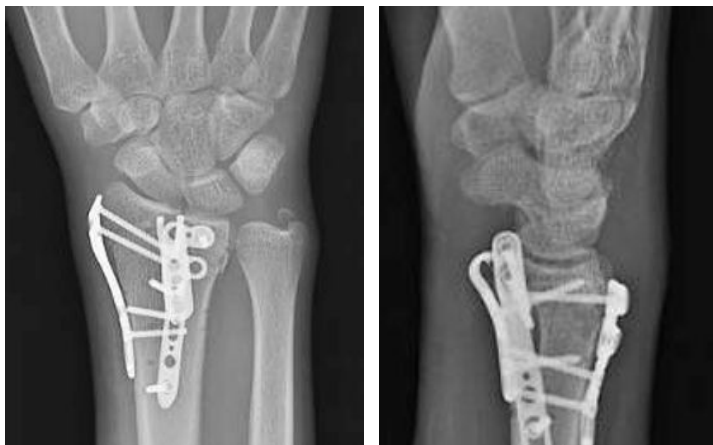The volar approach was further utilized to reduce and restore alignment of the radial column/ scaphoid facet. Dissection was performed deep to radial artery, releasing the deforming force of the brachioradialis off of the radial styloid. Radial column plate was then placed, allowing for 2 screws to be distal of fracture site. Provisional fixation was performed with K-wire and once again a non-locking screw was placed just proximal of fracture. Using locking guide, two distal locking screws were placed. Biplanar intraoperative x-ray was used to verify reduction.

Prior to closure of surgical incision, intraoperative x-ray, and direct visualization was use to verify reduction. Additionally, intra-operative range of motion of the wrist was performed, confirming operative stability and guiding more aggressive postoperative range of motion protocol.

Post-operative follow-up.

Post-operatively, the patient was placed in volar resting splint to allow for soft tissue rest and healing.

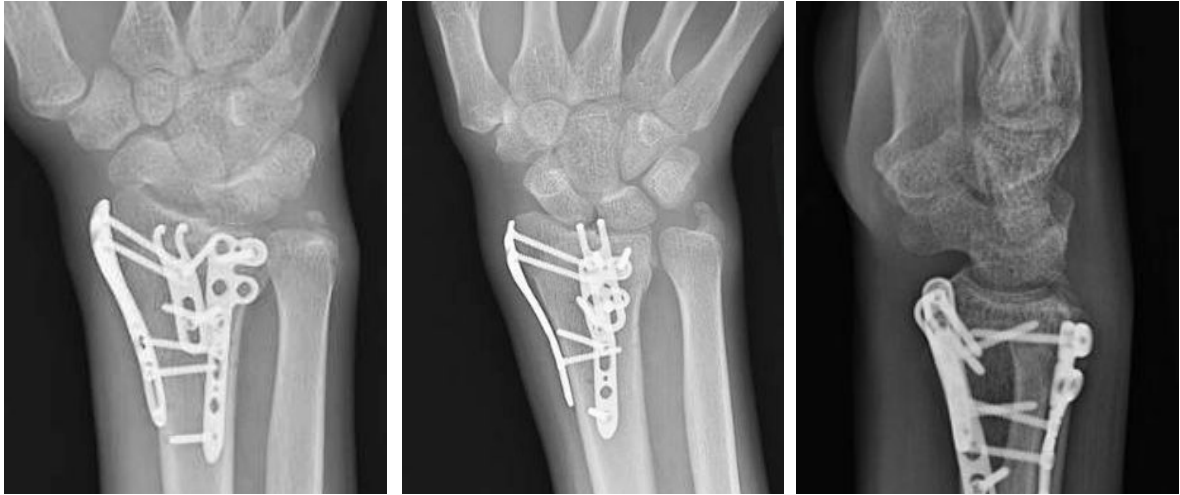
At the 2 week post-operative appointment, splint was removed. Radiographs showed no evidence of secondary displacement. The patient was taught self-directed therapy to allow for flexion, extension, supination, and pronation with active, active-assist and passive range of motion. 3 to 5 pounds (1 to 2 kg) weight bearing was allowed to encourage return to activities of daily life. A removable wrist splint was given for patient to wear when more durable activity was performed.



2 weeks post-op x-rays

NEW CLIP - TECHNIQS

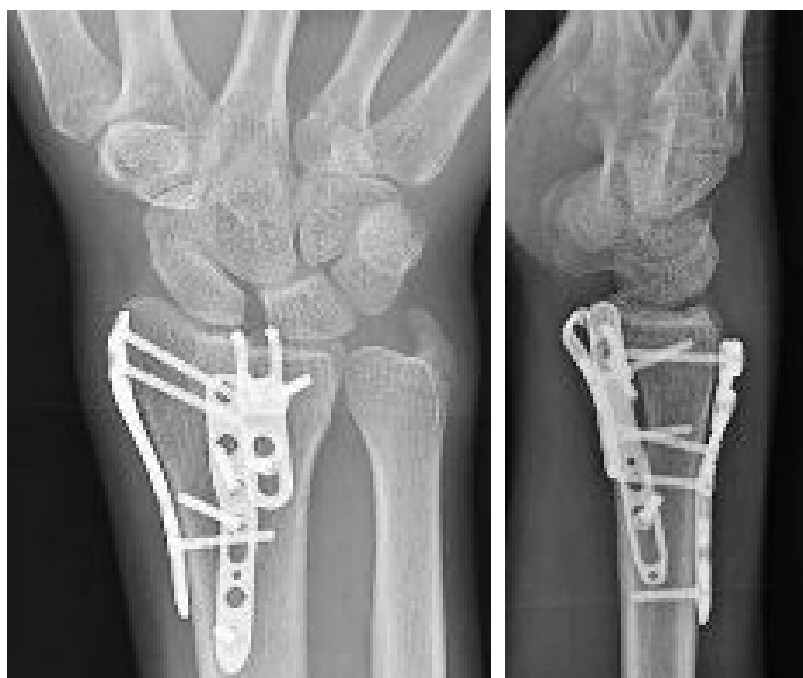Six-week follow up visit reveal appropriate interval consolidation at fracture site to allow progression of weight bearing as tolerated. Motion (when compared to contralateral extremity) at 6 week visit demonstrated full pronation and supination, while lacking approximately 20 degrees of extension and 30 degrees of flexion.



6 weeks post-op x-rays

Patient final post-operative visit at four months post-op showed x-ray with healed distal radius. Additionally, patient had minimal measurable deficits in motion lacking 5 degrees in extension and 10 degrees in flexion.

The patient had returned to manual labor on a ranch at approximately 8 week post-op, denying any function limitations when performing his job but occasionally wear a brace due to swelling. After 16 weeks, the patient denies any limitation and working lifting up to 125 pounds (56 kg) daily.



16 weeks post-op x-rays

Wrist	Pronation	Supination	Flexion	Extension
Left	85°	85°	95°	90°
Right (comparison)	85°	85°	105°	95°

Wrist mobilities' figures of the patient 4 months post-op

Physicians conclusions.

The surgical treatment of high energy, severely comminuted distal radius fractures has until recently been limited to external fixation and bridge plating. Newclip Technics offers the advantage of having a comprehensive fragment specific plating system, allowing multiple options to address this difficult fractures.

As was this case in this manual laborer, this allowed fragment directed fixation to reconstruct both the lunate facet and the radial column. Each plate offer combination holes which can be used for non-locking, fixed-angled locking, variable-angled locking, and the K-lock system. This helps ensure that adequate fixation and stabilization are achieved. Fragment specific plating systems offers a wide variety of plate with diverse possibilities. Newclip Technics package offers volar locking plates, volar rim plates, and the fragment specific plates with in a single tray, and allows for the surgeon to make the best intraoperative decision without concern.

Furthermore, Newclip ensures a top representative is present assisting in dialogue to make sure implants are used in ideal manner.

newcliptechnics.com



Manufacturer : Newclip Technics - Case Study EN - Xpert Wrist 2.4 Fragment Spe - ED1- 03/2024 - Medical device EC:
class IIb – CE1639 SGS BE

Results from any case studies reported in this presentation may not be predictive of results in other cases.
Read labelling and instructions before the use of Newclip Technics medical devices. These products must be handled
and/or implanted by trained and qualified staff who have read the instructions before use.